

Treatment Options for the Edentulous Mandible

The treatment of the edentulous mandible is one of the most challenging to the dental practitioner in regards to patient satisfaction.¹ The number of edentulous arches in the United States is expected to increase. It is estimated that by the year 2020 there will be 61 million edentulous arches.² As this segment of the population grows, there will be an increasing demand on dentistry for edentulous prosthetic treatment. This article discusses the treatment options available today for the edentulous mandible and the importance of mandibular anatomy in determining implant position, prosthesis selection, and cantilever length.

Steven Kendrick,
DDS,

David Wong,
DDS

ANATOMIC CONSIDERATIONS

The anatomy of the edentulous ridge provides challenges to the adaptive process of patients to conventional denture therapy. One of the anatomical considerations is the mandibular ridge, which provides less than one quarter the support offered by the peridontium to the natural teeth (Figure 1).³ It is from this compromised situation that the clinician must build the prosthesis. An understanding of the anatomy of the edentulous mandible will allow the clinician to make decisions on implant placement and any ancillary procedure that will need to be performed in order to obtain a satisfactory result for the patient.

The implant retained/supported prosthesis will be affected by the location of the mental foramina and the inferior alveolar canal (Figure 2). The distance between these areas will determine the number of possible implant sites as well as inter-implant spacing. The distance between the foramina is variable based on ethnicity, sex, and skull size. The average interforamen distance for African-American Males is 45.8 mm; white males is 45 mm; African-American Females is 43.8 mm; and white females is 41 mm.⁴ This space can be divided into 5 equal columns of bone serving as potential implant sites, labeled A, B, C, D, E, starting from the patient's right side (Figure 3). If fewer than 5 implants are being placed at the initial surgery, the implants are placed in different positions depending on the type of prosthesis being designed, leaving the appropriate columns empty for future implant placement should the patient want/need additional implant support.^{5,6}

As a general rule, when 5 implants are placed in the anterior mandible between the foramen, the cantilever should not exceed 2.5 times the anteroposterior (A-P) spread with all other force factors being low.⁷ The A-P distance is obtained by connecting a line drawn from the distal aspect of the most posterior implants and a parallel line drawn through the center of the most anterior implant (Figure 4). The greater the A-P distance the more favorable the situation for the posterior cantilever.^{8,9}

The existing arch form will affect the amount of A-P spread possible. There are 3

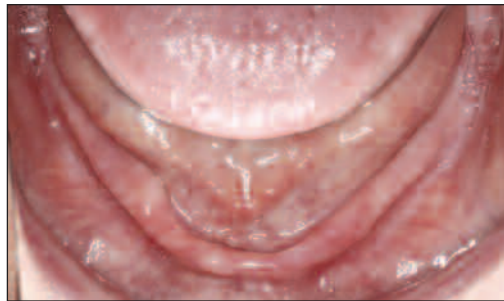

Figure 1. The edentulous mandibular ridge provides limited support for a conventional prosthesis.

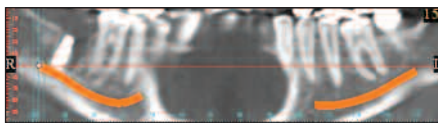

Figure 2. The position of the mental foramina and the inferior alveolar canal will determine the space available for implant placement.

types of arch forms: (1) ovoid, (2) tapering, and (3) square. The square arch form provides the shortest A-P spread, with an A-P dimension often of 2 to 5 mm. Conversely, the tapering arch form will result in the largest A-P spread, with an A-P distance greater than 8 mm. The ovoid, which is the most common, will often have an A-P distance of 6 to 8 mm.¹⁰ By evaluating the arch form, the doctor will have an idea of the potential A-P spread and the amount of cantilever possible to support the prosthesis (Figure 5). Patient force factors will ultimately determine the amount of cantilever to be used for the definitive prosthesis.¹¹

The treatment plan will also consider the alveolar ridge height and width. A minimum alveolar height of 9 mm is recommended if conventional endosseous implants are

expected to be used to ensure predictability.¹² In the anterior mandible the inferior cortical plate can be perforated but it is not recommended. Posterior to the mental foramen a safety zone of 2 mm superior to the inferior alveolar canal is suggested.¹³ The minimum width of the edentulous mandible is dependent on the type of implant used. A 1mm thickness of bone buccal and lingual to the implant ensures sufficient bone thickness and blood supply around the implant for predictable survival.¹⁴

The crown height space available will determine the type of attachment, material selection, or whether additional procedures must be performed to obtain the appropriate space for the desired prosthesis. This dimension will be the least with an implant attachment retained prosthesis (7 mm). The space required for the current lowest vertical height of an attachment (abutment plus male) is 3.17 mm on an externally hexed implant, and 2.5 mm on a nonhexed implant.

The bar retained implant overdenture will require 15 to 17 mm of crown height space depending on the type of attachment

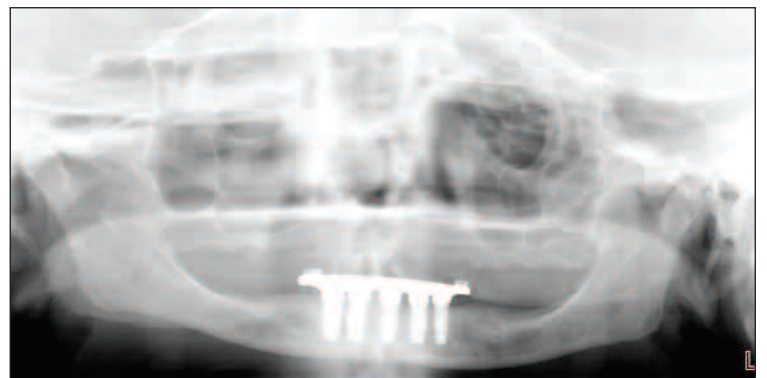


Figure 3. There are 5 columns of bone available for implant placement between the mental foramina.

used (Figure 6). When considering an implant retained fixed prosthesis the amount of crown height space present will determine the materials to be selected.

The amount of keratinized tissue present will determine if any soft tissue augmentation procedures will need to be performed either at the time of implant placement or in the future. Factors such as active/hyperactive gag reflex and parafunctional habits will also need to be considered.

PSYCHOLOGIC CONSIDERATIONS

Edentulous patients can present with some

continued on page ##

Treatment Options...

continued from page

psychological challenges related to their condition. Some edentulous patients cannot cope with their prosthesis regardless of how well it is made.¹⁵ This does not mean that all edentulous patients fall into this category. Just as with dentate patients, a pre-clinical interview where the clini-

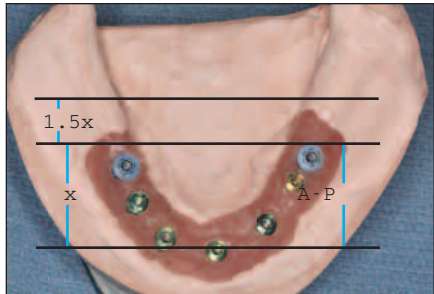


Figure 4. Potential anteroposterior (A-P) spread based on implant position.

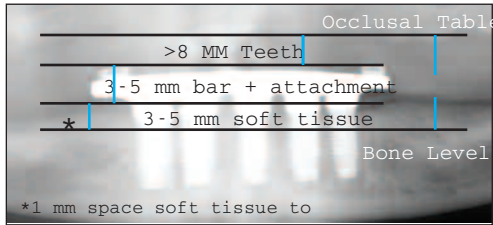


Figure 6. Vertical space requirements for a bar-retained overdenture.

cian and patient can discuss expectations is mutually beneficial.

CONVENTIONAL DENTURE

Conventional denture therapy is also an option for the patient, but often provides the least favorable outcome for patients when compared to implant supported prostheses. Patients report the most important qualities of a denture to be comfort, stability, the ability to chew and speak normally, and aesthetics.^{16,17} Multiple studies have compared conventional dentures to implant retained overdentures. In these studies patients had higher satisfaction scores with implant retained dentures as compared to conventional dentures.¹⁸

However, there are factors such as financial and/or health related limitations in which a conventional denture meets the need of that person and should not be considered inferior treatment.

MINI-IMPLANT RETAINED OVERDENTURE

A mini-implant retained mandibular denture should be considered as a treatment option when there is insufficient buccal-lingual width of the alveolar ridge for standard size endosseous implants and the patient cannot undergo grafting procedures, whether due to financial or health risk factors (Figure 7). There will also be a percentage of patients who will

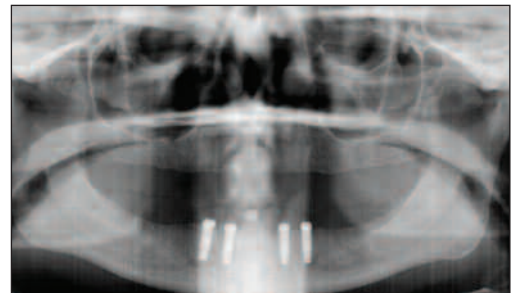
not consent to the grafting procedure due to a perceived negative risk/benefit ratio. Current mini-implants on the market range from 1.8 to 3.0 mm in diameter and length ranging from 10 to 18 mm. The number of implants recommended in the mandible is a minimum of 4 with a spacing of 5 to 8 mm between implants. The manufacturers also recommend a minimum distance of 7 mm anterior to the men-

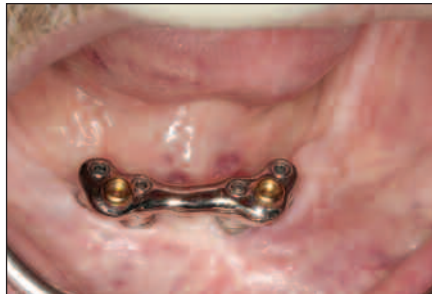

Figure 5. The square arch form of this patient has minimal A-P spread, leading to a short cantilever.

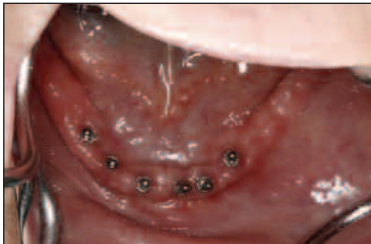

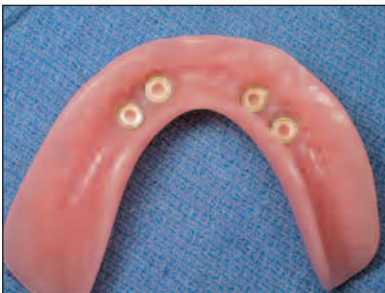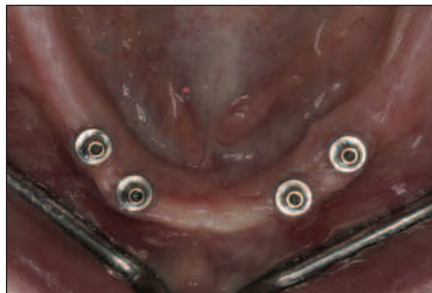Figure 7. Mini-implant placement in an atrophic mandibular ridge.



Figures 8 to 10. Attachment-retained implant overdenture with implants in the AB DE position.

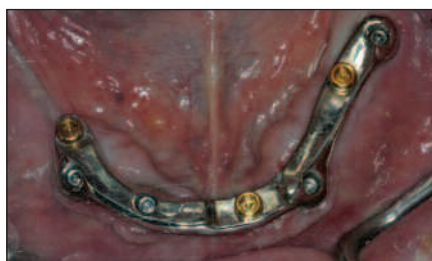

Figure 11. Bar-retained overdenture with an implant in the left first molar position to increase the A-P spread.

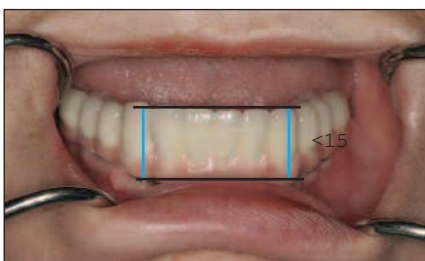


Figure 12. The distance from the implant platform to the occlusal table is less than 15 mm; the prosthetic material indicated is PFM.

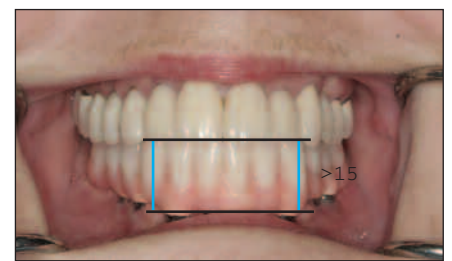

Figure 13. The distance from the implant platform to the occlusal table is greater than 15 mm; the hybrid prosthesis is the indicated restoration.

tal foramina. The total number of implants possible will be determined by the distance between the mental foramina. Immediate loading of the implants is recommended only when the implants are able to resist 30 to 35 ncm of load (as per manufacturer's instruction). At that time the mandibular denture is connected to the mini-implants using a chair-side pick-up technique, or an impression is taken and a laboratory relin process is preformed.

who is transitioning to a fixed prosthesis in the future or cannot afford the expense of a bar-retained overdenture will have the treatment option of a 4-implant-retained prosthesis with implants in the A-B-D-E positions.

The attachment-retained overdenture has the main advantage of cost over the bar-retained implant overdenture and the implant retained fixed prosthesis.^{21,22} However, it does not address posterior bone loss and will have less stability than a bar-

retained overdenture or a fixed prosthesis.²³

BAR-RETAINED IMPLANT OVERDENTURE

The bar-retained implant overdenture provides more support for the edentulous patient compared to the attachment-retained implant denture. The same implant placement options are available but the ability exists to cantilever the bar posteriorly due to A-P spread (Figure 11). The B-D, A-C-E, and B-C-D options are generally not cantilevered due to the limited implant support and short A-P distances. The A-B-D-E option in a tapering arch is often 10 mm, and 8 mm in an ovoid arch. If all other factors are favorable this would allow a cantilever in the ovoid arch of up to 12 mm, and up to 15 mm in the tapering arch. The square arch form would only allow 4 mm of cantilever.²⁴

If the patient requires more support an additional implant can be placed in the C position, which will increase the A-P distance in an ovoid or tapering arch. An implant can also be placed in the molar region on either side to increase the A-P distance. This is a primary option for increasing A-P spread in a square arch form.

IMPLANT-RETAINED FIXED PROSTHESIS

Patient desires will also dictate the fabrication of an implant-retained fixed prosthesis. The 5 columns of bone are still available to be used, with the option of placing implants above or behind the mental foramina to reduce cantilever lengths.

This prosthesis also has the poten-

continued on page ##

Treatment Options...

continued from page

tial of an increase of posterior bone height.^{25,26} One to 4 additional implants can be placed in the mandible after the A-B-D-E positions have been filled to gain the maximum A-P distance and increase implant support.

Further, crown height space will play a role in material selection for the prosthesis. If the distance from the implant platform to the occlusal table is less than 15 mm, then the prosthetic material indicated is PMF (Figure 12). If the distance is greater than 15 mm, then a hybrid prosthesis should be used (Figure 13).²⁷ The distance of 15 mm is important because of the physical properties of the restorative materials. Acrylic is a material that requires bulk for strength. If there is less than 15 mm of distance from the implant platform to the occlusal table there will not be sufficient space to achieve the bulk of acrylic necessary to provide strength for the prosthesis.

Likewise, PFM restorations have difficulties when too much space is available. At dimensions greater than 15 mm from the implant platform to the occlusal table, the control of surface porosity across the metal substructure becomes difficult due to variations in cooling and heating rates across the metal.²⁸ Because of this it becomes difficult to bake porcelain to the substructure. The result is the high possibility of future porcelain fracture.²⁹

CONCLUSION

An understanding of the anatomy of the mandible along with an understanding of the concept of A-P spread will allow the clinician to treatment plan patients with an edentulous mandible. Treatment options should be based on the patient's wants/desires for the final prosthesis. The 2-implant overdenture should be the starting point for treatment options, not the end point. If the patient is unable or unwilling to undergo grafting procedures, then the mini-implant option should be discussed, but it should not be seen as a treatment for every edentulous patient. The patient will ultimately make the decision based on what treatment option is in their best interest at that given point in their life. By understanding what is necessary to provide each of the treatment options discussed in this article, the clinician can formulate a plan to phase treatment for the patient and help them arrive at their ultimate goal once they have been informed of the pros/cons and consequences of no treatment. ♦

References

- Zarb GA, ed. *Osseointegration: On Continuing Synergies in Surgery, Prosthodontics, Biomaterials*. Chicago, Ill: Quintessence Publishing Co; 2008:4-13.
- Douglass CW, Shih A, Ostry L. Will there be a need for complete dentures in the United States in 2020? *J Prosthet Dent*. 2002;87:5-8.
- Zarb GA, Bolender CL, Eckert SE, et al (eds). *Prosthodontic Treatment for Edentulous Patients: Complete Dentures and Implant-Supported Protheses*. St. Louis, Mo: Mosby; 2004. [AUTHORS: NEED PAGE NUMBERS]
- Cutright B, Quillopa N, Schubert W. An anthropometric analysis of the key foramina for maxillofacial surgery. *J Oral Maxillofac Surg*. 2003;61:354-347.
- Misch CE. Implant overdentures relieve discomfort for the edentulous patient. *Dentist*. 1989;67:37-38.
- Misch CE. Mandibular overdenture treatment options. In: *Misch Implant Institute Manual*. Dearborn, Mich: Misch International Implant Institute; 1984. [AUTHOR: PLEASE PROVIDE PAGE NUMBERS]
- Misch CE. [AUTHOR: PLEASE PROVIDE CHAPTER TITLE] *Dental Implant Prosthetics*. St. Louis, Mo: Mosby; 2005:178.
- Brosky ME, Koriath TW, Hodges J. The anterior cantilever in the implant-supported screw-retained mandibular prosthesis. *J Prosthet Dent*. 2003;89:244-249.
- Misch CE. [AUTHOR: PLEASE PROVIDE CHAPTER TITLE] *Contemporary Implant Dentistry*. 3rd ed. St. Louis, Mo: Mosby; 2008:309.
- [AUTHOR: Reference Missing from list please provide]
- Misch CE. [AUTHOR: PLEASE PROVIDE CHAPTER TITLE] *Contemporary Implant Dentistry*. 3rd ed. St. Louis, Mo: Mosby; 2008:254.
- Goodacre CJ, Bernal G, Rungcharassaeng K, et al. Clinical complications with implants and implant prostheses. *J Prosthet Dent*. 2003;90:121-132.
- Misch CE. [AUTHOR: PLEASE PROVIDE CHAPTER TITLE] *Contemporary Implant Dentistry*. 3rd ed. St. Louis, Mo: Mosby; 2008:701.
- Misch CE. [AUTHOR: PLEASE PROVIDE CHAPTER TITLE] *Dental Implant Prosthetics*. St. Louis, Mo: Mosby; 2005:182.
- Zarb GA, Bolender CL, Eckert SE, et al (eds). *Prosthodontic Treatment for Edentulous Patients: Complete Dentures and Implant-Supported Protheses*. St. Louis, Mo: Mosby; 2004. [AUTHORS: PLEASE PROVIDE PAGE NUMBERS]
- Berg E. The influence of some anamnestic, demographic, and clinical variables on patient acceptance of new complete dentures. *Acta Odontol Scand*. 1984;42:119-127.
- Kent G. Effects of osseointegrated implants on psychological and social well-being: a literature review. *J Prosthet Dent*. 1992;68:515-518.
- Awad MA, Feine JS. Measuring patient satisfaction with mandibular prostheses. *Community Dent Oral Epidemiol*. 1998;26:400-405.
- Krennmair G, Ulm C. The symphyseal single-tooth implant for anchorage of a mandibular complete denture in geriatric patients: a clinical report. *Int J Oral Maxillofac Implants*. 2001;16:98-104.
- Feine JS, Carlsson GE, Awad MA, et al. The McGill consensus statement on overdentures. Mandibular two-implant overdentures as first choice standard of care for edentulous patients. Montreal, Quebec, May 24-25, 2002. *Int J Oral Maxillofac Implants*. 2002;17:601-602.
- Carlsson GE, Kronström M, de Baat C, et al. A survey of the use of mandibular implant overdentures in 10 countries. *Int J Prosthodont*. 2004;17:211-217.
- Palmqvist S, Owall B, Schou S. A prospective randomized clinical study comparing implant-supported fixed prostheses and overdentures in the edentulous mandible: prosthodontic production time and costs. *Int J Prosthodont*. 2004;17:231-235.
- Misch CE. [AUTHOR: PLEASE PROVIDE CHAPTER TITLE] *Contemporary Implant Dentistry*. 3rd ed. St. Louis, Mo: Mosby; 2008:294.
- Misch CE. [AUTHOR: PLEASE PROVIDE CHAPTER TITLE] *Contemporary Implant Dentistry*. 3rd ed. St. Louis, Mo: Mosby; 2008:307.
- Wright PS, Watson RM. Effect of prefabricated bar design with implant-stabilized prostheses on ridge resorption: a clinical report. *Int J Oral and Maxillofac Implants*. 1998;13:77-81.
- Misch CE. [AUTHOR: PLEASE PROVIDE CHAPTER TITLE] *Contemporary Implant Dentistry*. 3rd ed. St. Louis, Mo: Mosby; 2008:291.
- Reddy MS, Geurs NC, Wang IC, et al. Mandibular growth following implant restoration: does Wolff's law apply to residual ridge resorption? *Int J Periodontics Restorative Dent*. 2002;22:315-321.

To submit Continuing Education answers, use the answer sheet on page 86. Place an X in the box corresponding to the answer you believe is correct, detach the answer sheet from the magazine, and mail to Dentistry Today Department of Continuing Education. This article is available for 2 hours of CE credit.

The following 16 questions were derived from the article *Treatment Options for the Edentulous Mandible* by Steven Kendrick, DDS and David Wong, DDS, on pages xx through xx.

Learning Objectives

After reading this article, the individual will learn:

- Treatment options available today for the edentulous mandible.
- The importance of mandibular anatomy in determining implant position, prosthesis selection, and cantilever length.

1. The edentulous mandibular ridge provides less than _____ the support offered by the peridontium to the natural teeth.

- one third
- one fifth
- one half
- one quarter

2. The implant retained/supported prosthesis will be affected by the anatomic location of the _____ and the _____.

- mental foramina; inferior alveolar canal
- hyoglossis; inferior alveolar canal
- mental foramina; hyoid bone
- hyoglossis; hyoid bone

3. The anteroposterior distance is obtained by connecting a line drawn from the _____ aspect of the most _____ implants and a parallel line drawn through the center of the most anterior implant.

- distal; posterior
- mesial; posterior
- distal; anterior
- mesial posterior

4. The _____ arch form provides the shortest A-P spread with an A-P dimension often of _____ mm.

- ovoid; 8 to 9 mm
- square; 2 to 5 mm
- tapered; 1 to 2 mm
- square; 8 to 9 mm

5. What is the minimum distance required for an implant attachment retained overdenture, measured from the alveolar crest to the inner aspect of the lingual denture base?

- 5 mm
- 6 mm
- 7 mm
- 8 mm

6. The vertical component of the bar retained overdenture requires at least 15 to 17 mm of crown height space:

- 10 to 12 mm.
- 13 to 15 mm.
- 15 to 17 mm.
- 18 to 20 mm.

7. If the distance from the implant platform to the occlusal table is less than 15 mm, then the prosthetic material indicated for a fixed prosthesis is:

- PFM.
- acrylic-pressed-to-metal.
- composite resin.
- all metal.

8. The attachment-retained overdenture has the advantage of cost compared to the bar-retained implant overdenture. However, the former has less stability than the latter.

- The first statement is true, the second is false
- The first statement is false, the second is true
- Both statements are true
- Both statements are false

Now available online @ dentalcetoday.com. Simply log on and follow the easy directions. Certification will be sent to you via e-mail.

28. Bridger DV, Nicholls JI. Distortion of ceramometal fixed partial dentures during the firing cycle. *J Prosthet Dent.* 1981;45:507-514.
29. Bertolotti RL, Moffa JP. Creep rate of porcelain-bonding alloys as a function of temperature. *J Dent Res.* 1980;59:2062-2065.
-

Dr. Kendrick is in private practice in Midwest City, Okla, and is an instructor at the Tulsa Implant Institute. He can be reached via e-mail at skend22@hotmail.com.

Disclosure: Need

Dr. Wong is in private practice in Tulsa, Okla, and is an instructor at the Tulsa Implant Institute. He is a Board Certified Periodontist and can be reached via e-mail at david@tulsagums.com.

Disclosure: Need